

Care Commission
Ferozepur Road : 23210
Ravi Road : 23211
Gujranwala : 23212

I.D. Card # : _____
Date : 16.10.23



MAP Welfare Trust®
Middle East Association of Pakistanis
MAP Medical Center

Head Office: Khiaban-e-Karim, 19-Km Ferozepur Road,
Street # E-123, Near Metro Station# 24, Lahore. Ph: 042 3592 3522
Branch Office: MAP-II, Main Ravi Road, Near Pir Makki, Lahore. Ph: 042 3724 3522
Branch Office: Dhariwal, Gujranwala. Phone : 055 376 8070

ULTRASOUND OBSTETRICAL EXAMINATION

Patient Name Rahila Age 30yrs

FINDINGS

GESTATION : single : Twin : triplet :

ACTIVITY SEEN : Cardiac : alive Fetal Movement : _____

POSITION : Longitudinal Lie _____ Oblique Lie _____ Transverse Lie

PRESENTATION : Vertex : _____ Breech : _____ Shoulder : _____

PLACENTAL POSITION :

Fundal Marginal : _____ Complete Previa : _____

PLACENTAL MATURITY : Grade : 0 _____ I _____ II _____ III _____

AMNIOTIC FLUID : Normal : Absent _____ oligohdramnions _____

Polyhydramnios : _____

GESTATIONAL AGE:

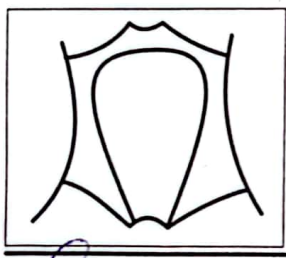
Gestational sac : _____ mm Corresponding to _____ Weeks _____ Days _____

BPD : 7.1 cm Corresponding to 30 Weeks _____ Days _____


CRL : _____ mm Corresponding to _____ Weeks

Femur : 6.2 cm Corresponding to 32 Weeks

FETAL POSITION



PLACENTAL POSITION



Comments : Singh alive (F) Transverse Placenta fundal
not ante AF. Adeq. Pl. Fuc EDD. 26.12.23

Any Abnormality : _____
Transverse Placenta (db)