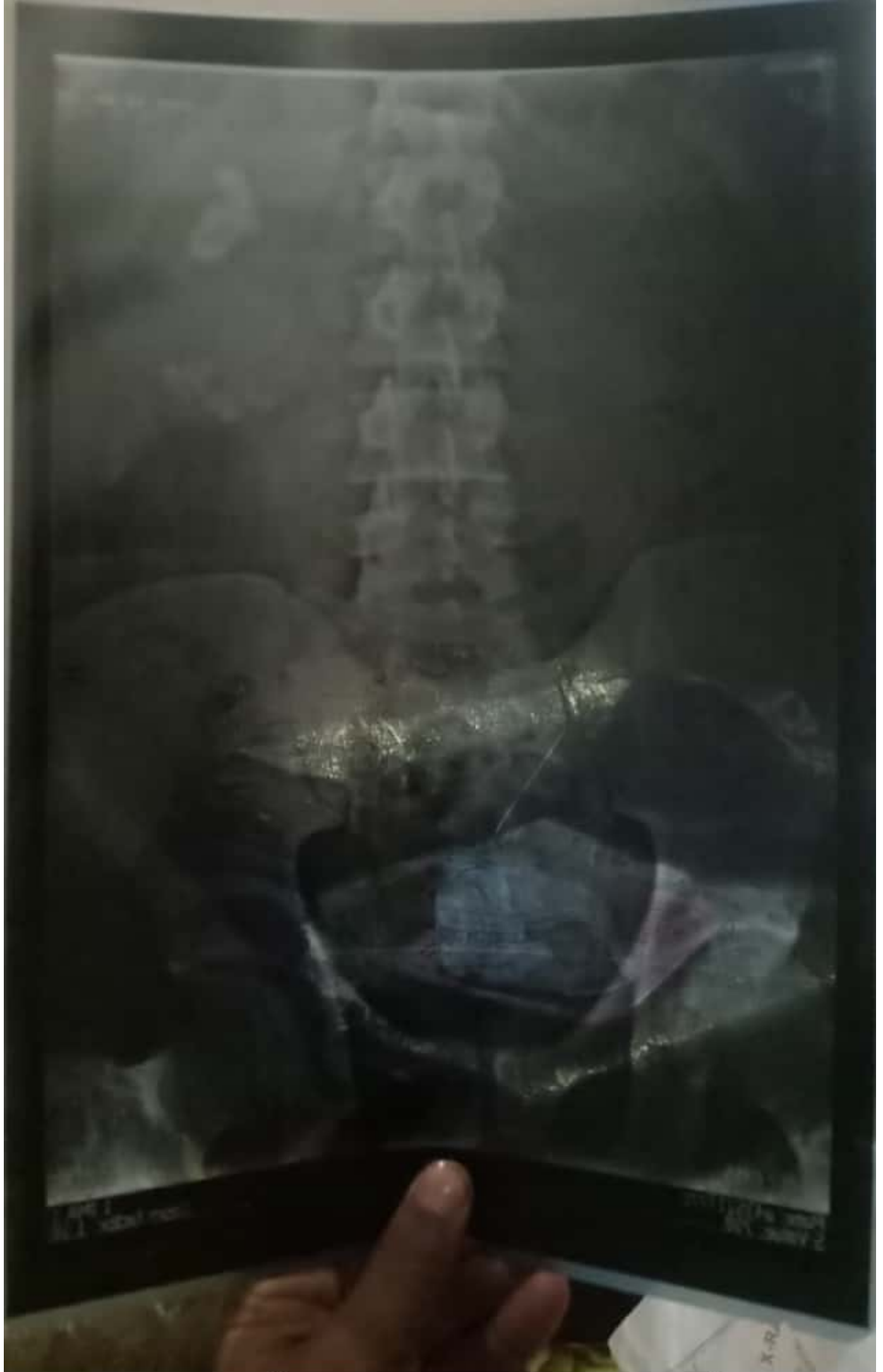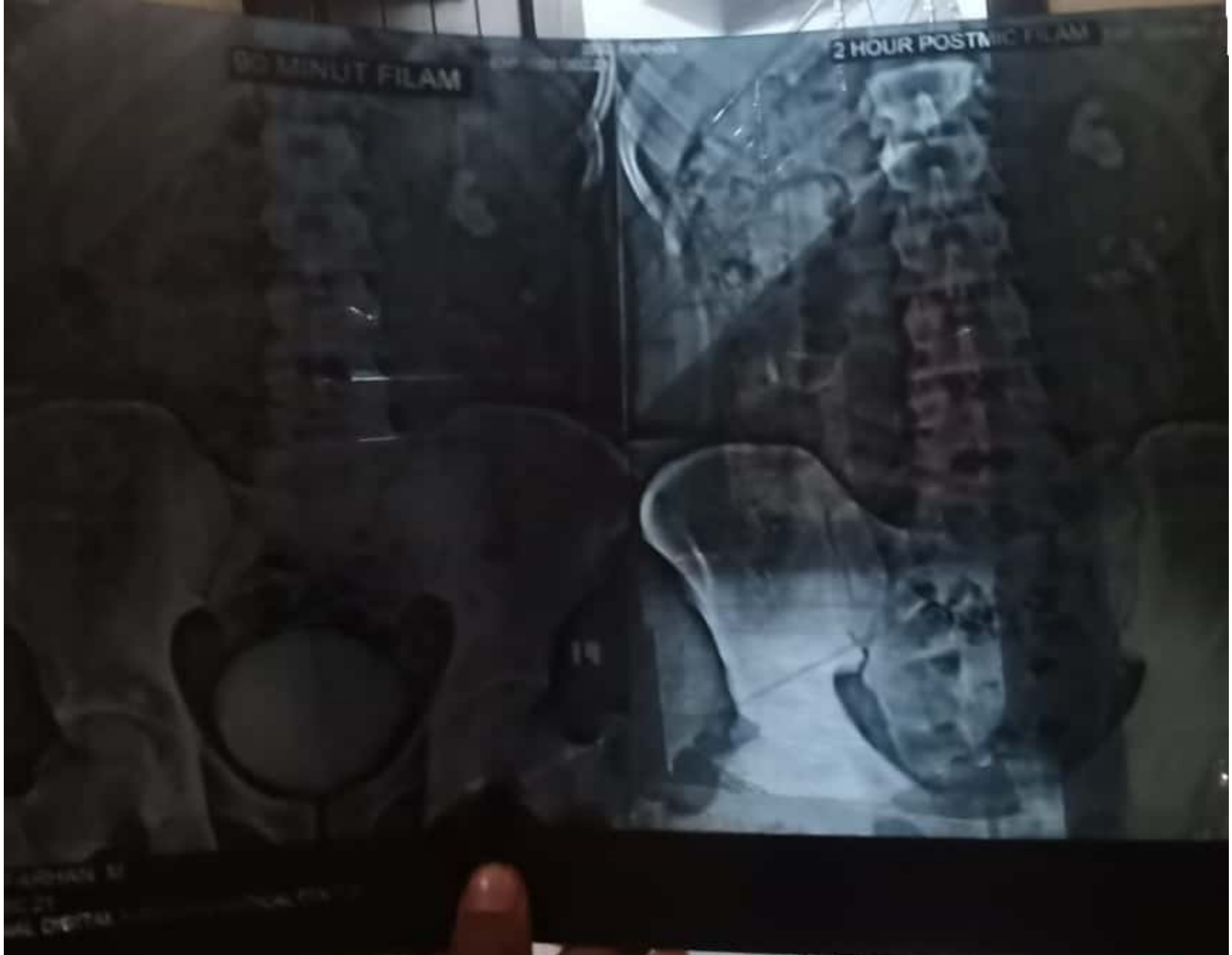




90 MINUT FILAM

2 HOUR POSTMIC FILAM



Ullah Khattak



ماہنامہ
ڈاکٹر اکرام اللہ خانک

Urinary
Kidney Diseases
Feshawat

PHD • M.B.B.S

Handwritten notes in Urdu, including a date '20/10/2019'.

Age Sex Date



Handwritten notes in Urdu describing a medical case. The text includes:
'L5/S1 Disc protrusion' (circled)
'To Disc' (with an arrow pointing to a diagram of a vertebra)
'To Spinal Cord' (with an arrow pointing to the spinal cord in the diagram)
'7' (at the bottom)

Assistant Professor
Dr. Ghulam Rasul

MBBS (Pesh)

MCPS, FCPS (Surgery)

FCPS Urology

General Surgeon

Laparoscopic Surgeon

Urologist

Chief District Specialist

Assistant Professor of Surgery

Incharge Surgical Department

Govt Naseer Ullah Khan Babar Memorial Hospital Peshawar.



اسٹنٹ پروفیسر
ڈاکٹر غلام رسول

ایم بی بی ایس (پشاور)
ایم سی پی ایس، ایف سی پی ایس (سرجری)
ایف سی پی ایس یورالوجی
جنرل سرجن
لاپروسکوپک سرجن
یورالوجسٹ
چیف ڈسٹرکٹ اسپیشلسٹ
اسٹنٹ پروفیسر آف سرجری
انچارج سرجیکل ڈیپارٹمنٹ
گورنمنٹ ناسیر اللہ خان بابار میموریل ہسپتال پشاور

Name: Farhan Address: Peshawar Date: 21/11/20

Pain in flamm



LI. NFK
E Calcule

چھٹی بروز: ہفتہ - اتوار

فون: 091-2593529, 091-2553441
موبائل: 0345-9199695

رست فلور روم 126-127 پاک میڈیکل سنٹر سوئیگار نو چوک خیبر بازار پشاور

0300 879 1819

RENAL PROFILE

	RESULT	UNITS	REFERENCE RANGE
Creatinine	28	mg/dl	10 — 50
BUN	1.0	mg/dl	0.6 — 1.5
Uric Acid (Urates)	4.9	mg/dl	M 3.4 — 7.0 F 2.4 — 5.7

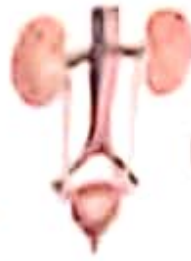CONSULTANT UROLOGIST

DR. KIFAYAT TARIQ

MBBS FCPS (Urology)

Registrar Institute of Kidney Diseases

Hayatabad Medical Complex Peshawar



ڈاکٹر کفایت طارق

ایم بی بی ایس، ایف سی پی (یورالوجی)

رجسٹرار انسٹیٹیوٹ آف کڈنی ڈیزیز ہیات آباد میڈیکل کمپلیکس پشاور

Patient Name: Tarique

Age: 22

Sex: M

Date: 20/11/2022

① flank pain on R side

duration / history

Stool habits on R side Constipation

No fever

o/c

o/c
① Abdominal
Swelling

Swelling

DTPA scan

Murad Colour Doppler Ultrasound, ECO & ECG

Dr. Din Moham
MCPS, FCPS Radilo
Dr. Yousaf Ali K
MBBS, MCPS DM
Radiology

Name FARHAN

Date, 16/12/20

Ref by DR IKRAMULLAH KHATTAK

U/S ABDOMEN AND PELVIS

Liver is of normal size (12.5 cm) and shape having smooth margins with normal parenchymal echotexture. No mass lesion seen.

Gall Bladder: No calculi. Wall thickness is normal.

Portal vein and CBD measures within normal limits.

Pancreas: Appears normal.

Spleen: Normal in size (11 cm), shape and echotexture.

Right kidney: Normal in size, shape and echogenicity. No evidence of stone or hydronephrosis.

Left kidney: Normal in size, shape and echogenicity. There are few calculi in interpolar region in close proximity largest one measures upto 12mm. However the possibility of staghorn could not be excluded. X ray KUB is suggested. There is gross hydronephrosis.

No ascites or abdominal lymphadenopathy.

Urinary bladder: Normal.

Prostate: Normal

IMPRESSION

Left renal stones with gross hydronephrosis