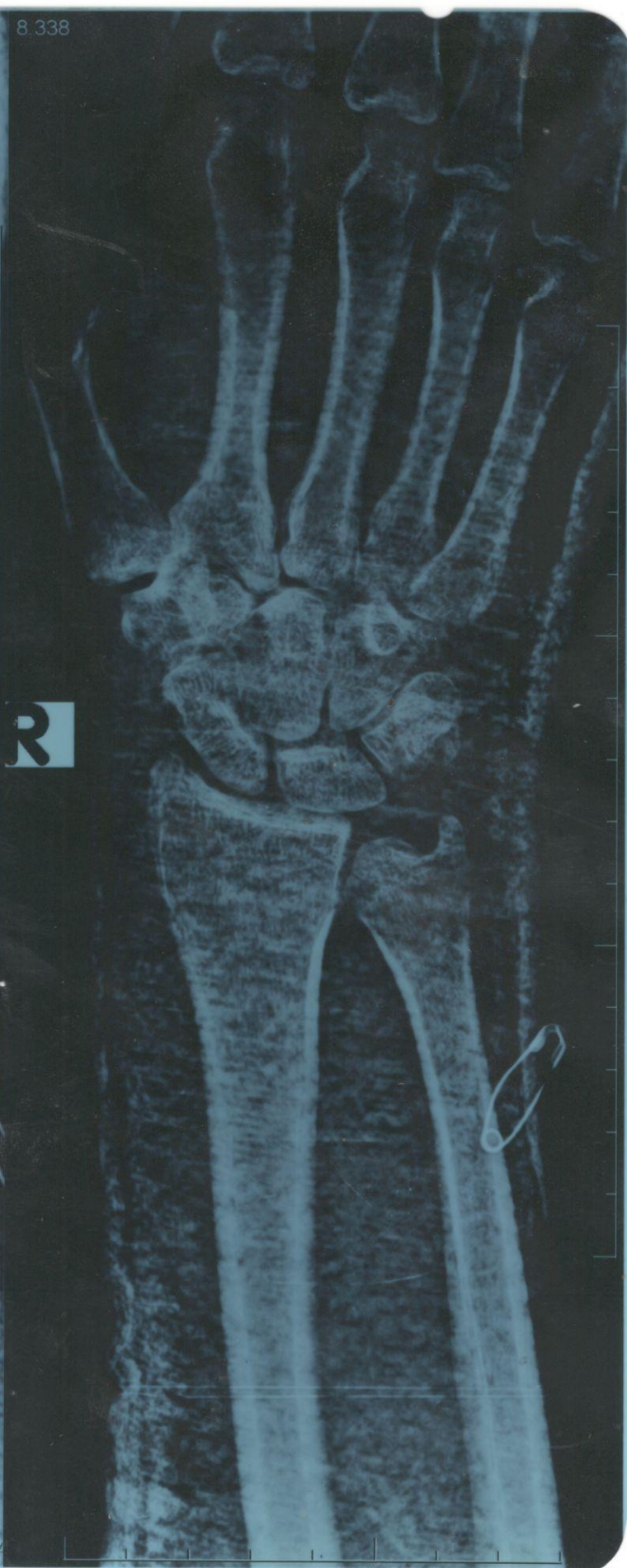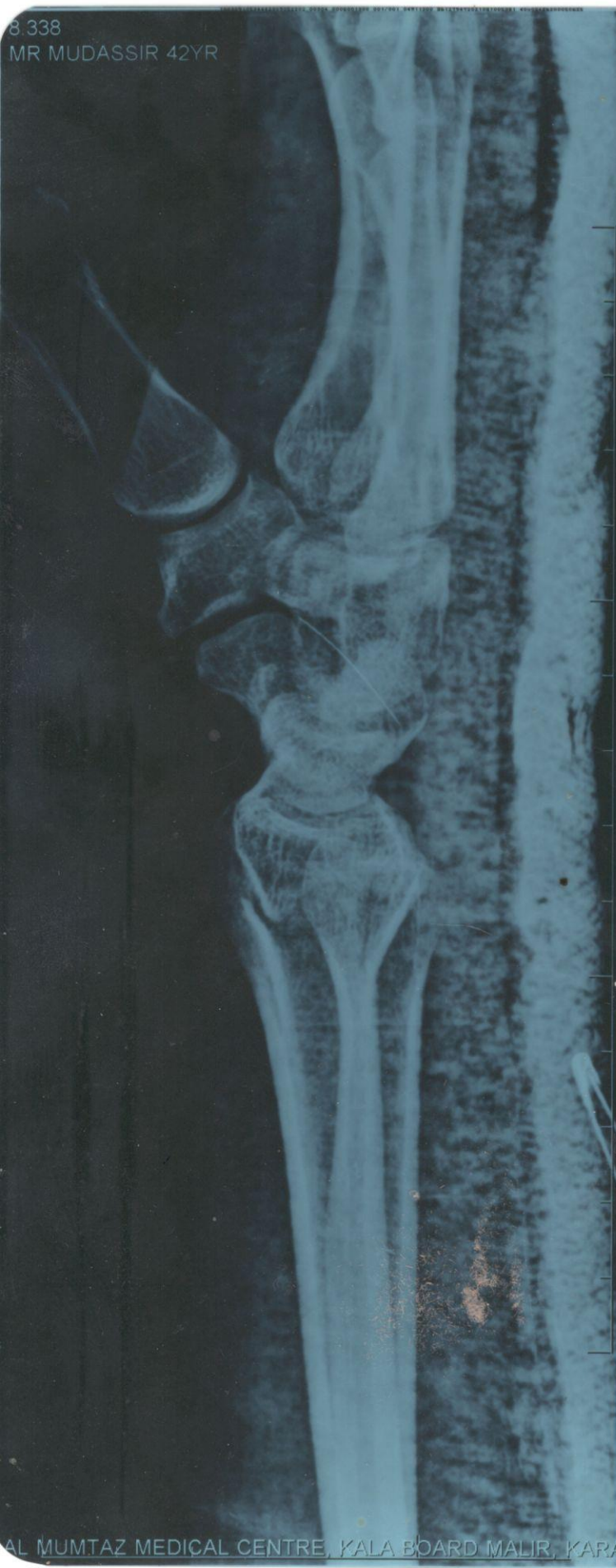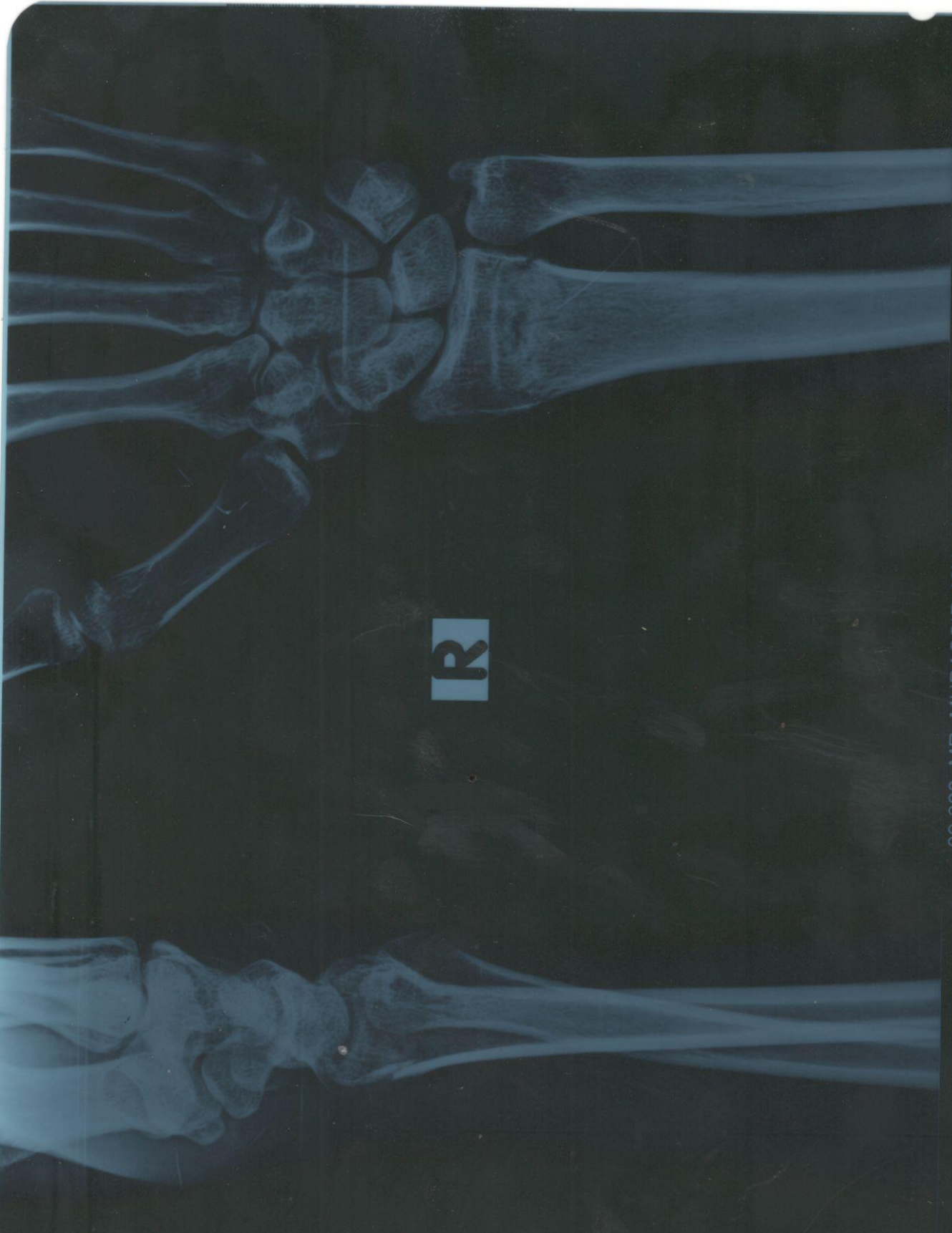


8 338  
MR MUDASSIR 42YR

8 338



**R**



R

09.388 MR. MUDASSIR 42Y M  
X-RAY RIGHT WRIST AP-LAT VIEWS  
REF. BY DR. ARIF SB  
2021.SEP.13

AL MUMTAZ MEDICAL CENTRE, KALA BOARD MALIR, KARACHI



R

The image displays two X-ray views of a right wrist. The top view is an Anteroposterior (AP) view, showing the distal radius and ulna, the scaphoid, lunate, triquetrum, and pisiform bones, and the base of the metacarpals. The bottom view is a lateral view, showing the distal radius and ulna from the side, highlighting the distal radioulnar joint and the relationship between the radius and ulna. A white rectangular marker with the letter 'R' is placed over the center of the AP view to indicate the right side.

08.957 MR. MUDASSIR 42Y M  
X-RAY RIGHT WRIST AP-LAT VIEWS  
REF. BY DR. ARIF SB  
2021.AUG.26

AL MUMTAZ MEDICAL CENTRE, KALA BOARD MALIR, KARACHI