



# LIAQUAT NATIONAL HOSPITAL

INSTITUTE FOR POSTGRADUATE MEDICAL STUDIES  
AND HEALTH SCIENCES

## Discharge Note For Reference

1189440

NOTE: This discharge note is not valid for any legal purpose.  
(Fresh Authority Letter is required for follow up treatment)

Case

Card No. 2022036206 Ward NS Room/Bed No. 2310

Name: Sheraz Imam F.W.S. D/o \_\_\_\_\_

Name of Company: Private Name of Specialist: Dr Salman

Date of Admission: 01-07-22 Date of Discharge: 03-07-22

Diagnosis: C3/4 PIT

Nature of Operation C3/4 Anterior Cervical Date of Operation 02-07-22  
*Procedures*  
Discectomy and Fixation + Drain  
*Placement*

Date and Type of Delivery \_\_\_\_\_

Whether left against Medical advice/cured/improved/recovered

Treatment: As per EMB

Advised Follow up to attend Dr Salman Yousuf Sharif O.P.D.

Cancer  No Cancer  Suspected Cancer

Signature of M.O. [Signature]

Full Name Dr Harmin Jamel Signature of Consultant \_\_\_\_\_

Registration No. \_\_\_\_\_

Signature of Patient/Receiver \_\_\_\_\_ Full Name \_\_\_\_\_



2310 Dle  
pt copy 36206

**Patient** MRN: A85-215-0322 Patient Name: SHERAZ IMAM Father Name:  
Gender: Male Age: 42Y 6M 0D

**Visit** Date/Time: 03-Jul-2022 14:01 Department: Neurosurgery Visit Type: Admission  
Priority: Routine Profile: Private

**Encounter** Date/ Time: 03-Jul-2022 14:03 Consultant: Salman Yousuf Sharif Encounter Type: Routine

**Presenting Complaints** 42 YEARS OLD MALE KC ITP, CAME WITH THE COMPLAIN OF  
-GAIT IMBALANCE FOR 4 MONTHS,  
- RIGHT HAND WEAKNESS FOR 3 MONTHS,

**History of Presenting Illness** ACCORDING TO THE PATIENT HE WAS IN HIS USUAL STATE OF HEALTH WHEN HE  
STARTED COMPLAINING OF GAIT IMBALANCE FOR 4 MONTHS FOLLOWED BY HISTORY OF  
GROUND LEVEL FALL 3 MONTHS AGO AND LATER OBSERVED RIGHT HAND WEAKNESS FOR  
3 MONTHS. PATIENT DOES NOT HAVE ANY NECK PAIN AND BRACHIALGIA. SPHINCTER IS  
NORMAL.

HOSPITAL COUURSE:  
PATIENT ADMITTED UNDER CARE OF DR SALMAN SHAREEF. HE UNDERWENT C3/4 ACDF.  
POST OPERATIVELY PATIENT WAS STABLE AND HENCE BEING DISCHARGED

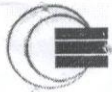
**Past History** GROUND LEVEL FALL 3 MONTHS AGO.  
KNOWN CASE OF ITP

**Operative Findings** ANTERIOR AND POSTERIOR OSTEOPHYTES  
POSTERIOINFERIOR DISC BULGE  
HYPERTROPHIED PLL

**Operations** PROCEDURE C3/4 ANTERIOR CERVICAL DISCECTOMY AND FIXATION + DRAIN PLACEMENT  
DATE: 02-07-22  
SURGEON: DR SALMAN SHAREEF  
ASSISTANT: DR YOUSUF, DR PRIYANKA  
ANAESTHETIST: DR SIRAJ

**General Physical Examination** ON ADMISSION  
BP: 120/80  
TEMP: 98  
PULSE: 80  
RESP RATE: 20

ON DISCHARGE  
BP: 140/90  
PULSE: 80  
RESP RATE: 20  
TEMP: A/F

**LIAQUAT NATIONAL HOSPITAL AND MEDICAL COLLEGE**

Institute for Postgraduate Medical Studies &amp; Health Sciences

---

**Patient** MRN: A85-215-0322 Patient Name: SHERAZ IMAM Father Name:  
Gender: Male Age: 42Y 6M 0D

---

**Visit** Date/Time: 03-Jul-2022 14:01 Department: Neurosurgery Visit Type: Admission  
Priority: Routine Profile: Private

---

**Encounter** Date/ Time: 03-Jul-2022 14:03 Consultant: Salman Yousuf Sharif Encounter Type: Routine

---

**Systemic Examination**

CHEST: NVB  
CVS: S1+S2+0  
ABDOMEN: SOFT + NON TENDER  
CNS: GCS: E4M6V5

PREOP  
POWER  
LOWER LIMB:  
HF: RIGHT 5 LEFT 5  
KE: RIGHT 5 LEFT 5  
DF: RIGHT 5 LEFT 5  
PF: RIGHT 5 LEFT 5  
EHL: RIGHT 5 LEFT 5

UPPER LIMB:  
SA: RIGHT 5 LEFT 5  
EF: RIGHT 5 LEFT 5  
EE: RIGHT 5 LEFT 5  
WE RIGHT 5 LEFT 5

HOFFMAN BILATERALLY +VE (L>R)  
REFLEXES +3

POST OP  
POWER  
LOWER LIMB:  
HF: RIGHT 5 LEFT 5  
KE: RIGHT 5 LEFT 5  
DF: RIGHT 5 LEFT 5  
PF: RIGHT 5 LEFT 5  
EHL: RIGHT 5 LEFT 5

UPPER LIMB:  
SA: RIGHT 5 LEFT 5  
EF: RIGHT 5 LEFT 5  
EE: RIGHT 5 LEFT 5  
WE RIGHT 5 LEFT 5

HOFFMAN BILATERALLY +VE (L>R)  
REFLEXES +3

**Final Diagnosis**

C3/4 PIT





---

**Patient** MRN: A85-215-0322 Patient Name: SHERAZ IMAM Father Name:  
Gender: Male Age: - 42Y 6M 0D

---

**Visit** Date/Time: 03-Jul-2022 14:01 Department: Neurosurgery Visit Type: Admission  
Priority: Routine Profile: Private

---

**Encounter** Date/ Time: 03-Jul-2022 14:03 Consultant: Salman Yousof Sharif Encounter Type: Routine

---

**Investigations**

23-06-22  
HB: 14.3  
WBC: 9.8  
PLATELETS: 125

01-07-22  
PY: 10.1  
INR:1.01  
APTT: 22  
UREA: 25  
CREATININE: 1.18  
NA: 139  
K: 3.2  
HCO3: 28  
TSH: 1.6

**Treatment**

- CAPSULE CEFSPAN 400MG 1+0+0 (3DAYS)
- SYP LYSOVIT 2TSP 2+0+2
- SKILLAX DROPS 25 DROPS AT NIGHT
- PAINCURE GEL WITH HEAT PAD 6 HOURLY
- TAB PANADOL 2+2+2
- TAB TERNALIN 2 MG 0.5 +0+1
- CAPSULE TRAMAL SR 1+0+1
- TAB MOTILIUM 10MG 1+0+1

**Followup** FOLLOWUP AT NEUROSURGERY OPD TO DR SALMAN SHAREEF ON 08-07-22,AT 9 AM

**Doctor Advise** ALTERNATE DAY DRESSING  
AVOID COUGH AND CONSTIPATION  
REPORT IN ER IN CASE OF FEVER, SEVERE PAIN OR WOUND DISCHARGE

3-Jul-22 14:29  
Printed On

amna.ghouri  
Created By

amna.ghouri  
Printed By



**PATEL HOSPITAL**  
A Project of Patel Foundation

ICN 0027  
WEB COM.

M.R. # : \_\_\_\_\_

*Shereaz*

Date : \_\_\_\_\_

*11/3/22*

Patient's Name : \_\_\_\_\_

Doctor's Name : \_\_\_\_\_

*DR Muhammad Shariq*

R

*Tas Syngster 1001*

*- cap Neo Gas 100mg  
1-001*

*- Tas Delta cortisol sy.  
1-001*

*- cap Risk 20mg  
1-001*

4, Gulshan-e-Iqbal, Karachi-75300, Pakistan  
11-174-174, +92 21 3865 8894, Fax: +92 21 3498 5899  
patel-hospital.org.pk, marketing@patel-hospital.org.pk  
org.pk patel.hospital patel\_hospital  
hospital.org.pk



Signature & Stamp of Consultant

For Appointment Please Call at +(92 21) 3498 6956-7

This document is not valid for legal purpose.



**PATEL HOSPITAL**  
A Project of Patel Foundation

Date: 03-6-22

Patient's Name Mr. Shervaz Tamwar Age: 43 yrs

M.R. #: \_\_\_\_\_ Consultant's Name: Rafiq

? ITP

Bone Marrow aspirate  
trephine

Case

Tab. Folic acid 1000  
 Tab. Meeobal 1000  
 Tab. Moduretic 1000  
 Evion 4000  
 1000

Cap. Rysel 2000  
 Folic acid 1000  
 Evion 4000

*[Handwritten Signature]*

ST-18, Block 4, Gulshan-e-Iqbal, Karachi-75300, Pakistan  
 Tel : +92-21 111-174-174, +92-21 3865 8894, Fax : +92 21 3498 5899  
 E-mail : info@patel-hospital.org.pk, marketing@patel-hospital.org.pk  
 patel-hospital.org.pk patel.hospital patel\_hospital  
**www.patel-hospital.org.pk**



Signature & Stamp of Consultant

For Appointment, Please Call at +(92 21) 3498 6956-7



Date:

15-5-22

Patient's Name

Mr. Sheeraz Imran

Age

43 year.

M.R. #:

Consultant's Name:

Patel



PATEL HOSPITAL  
A Project of Patel Foundation

EMC

- HB5AS, Anti HCV.

- GA PT.

S. Piz 4 Folate

Folic Acid

1/2

- Inj. Dexam 9are 1/1000 D.

1/2

Inj. 400

1/1000 D.

1/2

1/2

- Tab. Folic acid 1000.

- Tab. Mecloral 1000.

- Tab. serrafis 3000 1000

- Tab. Modusetic 1000.

- cap. Gabica 500

1000.

ST-18, Block 4, Gulshan-e-Iqbal, Karachi-75300., Pakistan  
Tel : +92-21 111-174-174, +92-21 3865 8894 Fax : +92 21 3498 5899  
E-mail : info@patel-hospital.org.pk, marketing@patel-hospital.org.pk  
patel-hospital.org.pk patel.hospital patel\_hospital  
www.patel-hospital.org.pk



Signature & Stamp of Consultant

For Appointment, Please Call at +92 21 3498 6956-7

Patel